

## Umbilical Restoration in Abdominoplasty A Simple Rectangular Technique

Luis López Tallaj, MD and  
José de Gervais, MD

+ Author Affiliations

### Abstract

**Background:** Many surgical procedures for reconstructing the umbilicus during dermolipectomy have been described.

**Objective:** The authors present a simple technique for umbilicus restoration in abdominal dermolipectomy to improve the shape of the umbilicus and disguise the periumbilical scar.

**Methods:** A skin incision was made to free the umbilicus from its original position. Two fixation points, at the 6-o'clock and 12-o'clock positions, 5 mm under the margin of the umbilicus, were employed to attach the umbilicus to the aponeurosis of the linea alba and the xiphoumbilical line, respectively. The index finger was inserted through the lower abdominal incision, after which the location of the umbilicus was palpated and marked on the abdominal skin 0.5 cm under the projected position of the neoumbilicus. A rectangle was drawn on the abdominal skin, marking the neoumbilical position. After skin incision around the neoumbilical position, subcutaneous fat was removed with scissors.

**Results:** From February 1999 to June 2003, the procedure was performed in 142 patients, with good results and only minor complications.

**Conclusion:** The rectangular technique for restoration of the umbilicus is a simple, successful, and safe procedure.

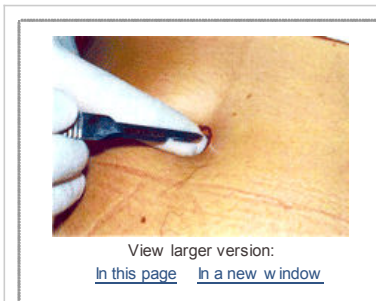The umbilicus as described in the literature is a 1.5- to 2-cm-diameter depressed scar, surrounded by a natural skin fold, anatomically situated at the level of the superior iliac crests.<sup>1, 2</sup> Many surgical procedures for reconstructing the umbilicus during dermolipectomy have been described. Some authors have proposed using a different array of skin incisions to improve the shape of the umbilicus and disguise the periumbilical scar.<sup>1, 3-5</sup> Others defend the use of a conchal cartilage composite graft as the donor area to re-create the shape of the umbilicus.<sup>6</sup>

Most of existing procedures propose a circular skin incision of the umbilical cone to free it from its original position. The biological development of a circular scar eventually leads to retraction of the circular incision and therefore to stenosis of the neoumbilicus.

We propose a simple procedure that permits restoration of the umbilical anatomy and concealment of the scar, which is buried around the umbilicus, leaving only its inferior margin visible.

### Surgical technique

The first half of umbilicus restoration comprised a skin incision to free the umbilicus from its original position. After marking the incision area, we positioned an index finger in the umbilical cavity and cut around the mark, freeing the umbilicus cone in a circle of tissue ([Figure 1](#)) measuring 1.5 cm in diameter.

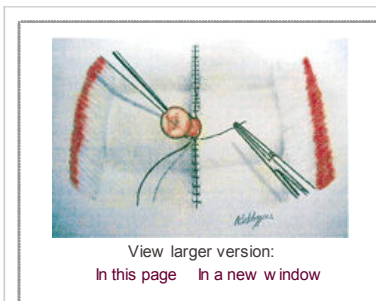


**Figure 1**

A circle was drawn and an incision made around an index finger positioned in the umbilicus cavity to free the circular cone.

View larger version:  
[In this page](#) [In a new window](#)

After removing the excess abdominal skin, we repositioned the neoumbilicus. Two fixation points 5 mm under the umbilicus margin, one at the 6 o'clock and one at the 12 o'clock position, were employed to attach the umbilicus to the aponeurosis of the linea alba and the xiphoumbilical line, respectively, with nylon 3-0 sutures ([Figure 2](#)).




**Figure 2**

Fixation was performed 5 mm under the umbilicus margin with nylon 3-0 sutures at the 6-and 12-o'clock positions.

View larger version:  
[In this page](#) [In a new window](#)

After guide sutures were placed to approximate the abdominal flap and the pubic area, the position of the umbilicus on the abdominal skin was determined. An index finger was inserted through the lower abdominal incision, after which the location of the umbilicus was palpated and its position marked directly above on the abdominal skin, 0.5 cm under the projected position of the neoumbilicus, so that when we removed the skin, it opened vertically a little more than 1 cm. This technique released tension on the pubic incision, making it easier to reapproximate.

A rectangle was drawn on the abdominal skin at the neoumbilical position ([Figure 3, A and B](#)). The A-B line should not exceed 2 cm, and the A-A line should not exceed 0.5 cm. Subcutaneous fat was removed with a pair of scissors after the skin incision around the neoumbilical position was made.



**Figure 3**

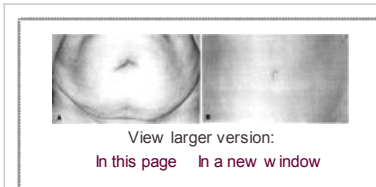
**A**, Drawing of the rectangular marking at the superior and inferior poles over the abdominal wall skin. **B** View of the umbilical cone after rectangular incision was made through the abdominal wall.

#### Postoperative care

A gauze dressing saturated with Vaseline was kept over the entire umbilical area during the immediate postoperative period. The patient was instructed to keep the dressing on for 4 days then to change it every day after bathing, and to use a mild topical corticoid and gauze to fill the umbilicus. After 3 weeks, a small marble sphere was placed in the umbilicus and kept in place for 3 months to maintain shape and compress the scar until it flattened.

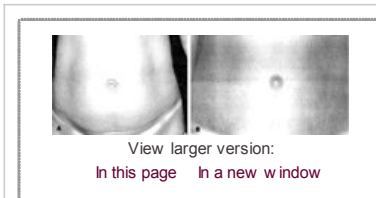
#### Results

The procedure was performed in 142 patients between February 1999 and February 2003. Typical results are illustrated in [Figures 4 and 5](#). There were 4 complications, including 1 incident of dehiscence of the umbilical scar that was treated with dressings, and 3 cases of hypertrophic scarring treated with triamcinolone spray with excellent results.



**Figure 4**

**A**, Preoperative view of a 69-year-old woman. **B**, Postoperative view 1.5 years after abdominoplasty, demonstrating the natural aspect of the umbilicus, with a practically unnoticeable scar.



**Figure 5**

**A**, Preoperative view of a 42-year-old woman. **B**, Postoperative view 1 year after abdominoplasty, with a hidden scar buried around the umbilicus.

#### Discussion

The umbilicus is a neonatal scar that remains invisible because it is hidden in the back of the cavity. It is essential to the abdominal contour in that it helps define the median abdominal sulcus, contributing to the proportionate curve of the inferior abdomen.<sup>7</sup> Many techniques have been proposed to reposition the umbilicus.<sup>1, 3, 4</sup> In our study we propose a new approach to repositioning the umbilicus that is easy to perform, provides the surgeon with a technical advantage by decreasing the tension on the abdominal flap, and yields excellent results. Maintaining the anatomic shape and integrity of the umbilicus is also important in preserving its role as a sexual focus.<sup>8</sup>

#### Conclusion

The rectangular technique for restoration of the umbilicus is a simple procedure that allows concealment of the periumbilical scar with few complications.

© 2003 American Society for Aesthetic Plastic Surgery

#### References

- Baroudi R, Baroudi R. Umbilicoplasty. *Clin Plast Surg* 1975;2:431-448. [Medline](#)
- Dubou R, Ousterhout DK, Dubou R, Ousterhout DK. Placement of the umbilicus in an abdominoplasty. *Plast Reconstr Surg* 1978;61:291-293. [Medline](#)
- Massiha H, Monteaut W, Phillips R, Massiha H, Monteaut W, Phillips R. A method of reconstructing a natural looking umbilicus in abdominoplasty. *Ann Plast Surg* 1997;38:228-231. [Medline](#)
- Itoh Y, Arai K, Itoh Y, Arai K. Umbilical reconstruction using a coneshaped flap. *Ann Plast Surg* 1992;28:335-338. [CrossRef](#) [Medline](#)
- Cannistra G, Pecorelli E, Cannistra G, Pecorelli E. Umbilical restoration in abdominal dermolipectomy: a simple double-Y, double-M technique. *Aesthetic Plast Surg* 1999;23:364-366. [CrossRef](#) [Medline](#)
- Matsuo K, Kondoh S, Hirose T, Matsuo K, Kondoh S, Hirose T. A simple technique for reconstruction of the umbilicus using a conchal cartilage composite graft. *Plast Reconstr Surg* 1990;86:149-151. [Medline](#)
- Craig SB, Faller MS, Puckett CL, Craig SB, Faller MS, Puckett CL. In search of the ideal female umbilicus. *Plast Reconstr Surg* 2000;105:389-392. [CrossRef](#) [Medline](#)
- Brown ES, Brown ES. The umbilicus as sexual focus. *Int J Psychoanal* 1997;78:577-578. [Medline](#)

